



### Unsure of which wormer to use?

With the grazing season upon us, why not bring a same day dung sample from your horse to either North Tawton, Hatherleigh or Okehampton to have a Worm Egg Count carried out in our in house labs

### Castration

With the weather improving, the ground drying and flies rapidly appearing, now until the end of May weather permitting is a good time to consider castrating or leaving it until the Autumn. Please call us if you would like to get booked in or have any questions/concerns about castrations

### Vaccinations

Unsure when your horse's next vaccination is due?

Why not call our reception team when you have your passport to hand and we can look at the dates with you.

Nothing more annoying than having to go the expense of a new course!

Our computer system does its best to send out reminders but please do not just rely on a reminder!

APRIL 2023

## EQUUS VETS APRIL NEWSLETTER 2023

FOR BREEDING, FOR SPORT FOR LIFE

Providing you with a dedicated and experienced equine only vets, 24 hours a day in Devon and East Cornwall



We are all welcoming the Spring weather with the longer days and the sun shining!



As the saying goes 'NO FOOT NO HORSE'.

Please find below an informative read on foot balance x rays by our vet Aeisha

### FOOT BALANCE X RAYS: NOT JUST FOR LAMINITICS

### WE ARE OFFERING FOOT BALANCE X RAYS FOR £200 INC VAT

*(Visit and sedation if required in addition to this price)*

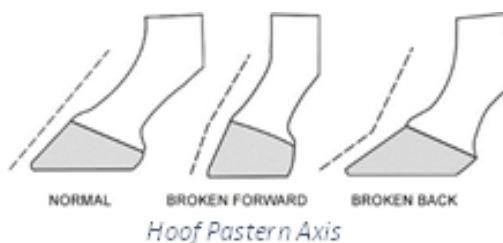#### What are foot balance x rays?

- Foot balance x rays are used to assess the structures within the foot, aswell as the relationship between the bones of the foot and pastern.
- Foot balance x rays are obtained by taking lateral (side-on) and dorsoproximal (front on) view of each foot
- X rays are usually taken of either the forelimbs only or all four feet

#### What do we assess with foot balance x rays?

Foot balance x rays are used to assess a variety of parameters, this can include:

- The relationship between the pedal bone and the hoof wall (for example sinking or rotation of the pedal bone in cases of laminitis)
- The length of the heels and the toes
- The relationship between the pedal bone and pastern, known as the hoof pastern axis
- The depth of the sole
- The symmetry of the foot and the structures within it



## EQUUS VETS


COVERING DEVON AND EAST CORNWALL

HEAD OFFICE: 64 FORE STREET, NORTH TAWTON, DEVON, EX202DT

DISPENSE COLLECTION POINTS HOLSWORTHY, HATHERLEIGH, OKEHAMPTON

01837 214004 – [info@equusvets.co.uk](mailto:info@equusvets.co.uk) – [www.equusvets.co.uk](http://www.equusvets.co.uk)





## MAY BANK HOLIDAYS

OUR SURGERIES WILL BE CLOSED FOR THE FOLLOWING DATES IN MAY BUT AS ALWAYS WE WILL PROVIDE AN ON CALL 24 HOUR EMERGENCY SERVICE

MONDAY 1<sup>ST</sup> MAY

MONDAY 8<sup>TH</sup> MAY

MONDAY 29<sup>TH</sup> MAY

WE HAVE A SKILLED AND EXPERIENCED TEAM WHO OFFER A WIDE RANGE OF SERVICES TO SUIT YOU AND YOUR HORSE.

LAMNESS EXAMINATIONS

DENTAL EXAMINATIONS AND TEETH RASPING

GASTROSCOPE AND ENDOSCOPE

PRE-PURCHASE EXAMINATIONS

IN-HOUSE LABORATORY

LEISURE HORSE PLAN

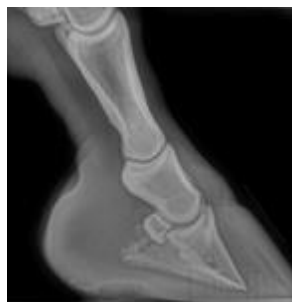COMPETITION HORSE PLAN

### What sort of cases are they useful for?

For sound horses, optimizing foot balance is important for preventing injuries. Correcting any issues with foot balance is also important in rehabilitating and managing certain lamenesses.

Foot balance x rays can be helpful for a wide variety of cases, such as:

- Management of long-term lameness such as navicular syndrome and osteoarthritis
- Treatment and prevention of some soft tissue injuries, for example suspensory injuries
- Treatment of laminitis, especially if there has been dropping or rotation of the pedal bone



*X ray from a laminitic pony showing dropping and rotation of the pedal bone*

### We have got foot balance x rays, what now?

Once the x rays have been taken, we will be able to identify any problems and make recommendations to rectify them

- These changes can range from simple changes such as altering the breakover point of the foot to using a different type of shoe or adding an impression material or pads
- It may be helpful to take x rays with your farrier to get a 'before' and 'after' image of the feet and assess whether the correction has been adequate

If you wish to discuss your horse further with a vet, please contact us on 01837 214004.

## IS YOUR HORSE ON MEDICATION FOR CUSHINGS??

We are pleased to announce that we are able to offer a cheaper alternative to Prascend. The drug is called Pergoquin and is every bit as effective.



### CORNWALL AREA DAYS FOR MAY 2023

11<sup>TH</sup> MAY

24<sup>TH</sup> MAY

EQUUS VETS

COVERING DEVON AND EAST CORNWALL

HEAD OFFICE: 64 FORE STREET, NORTH TAWTON, DEVON, EX202DT

01837 214004 – [info@equusvets.co.uk](mailto:info@equusvets.co.uk) – [www.equusvets.co.uk](http://www.equusvets.co.uk)

